



HISTOLOGICAL STUDY OF THE EFFECTS OF STEROIDAL AND NON-STEROIDAL ORAL CONTRACEPTIVES ON THE THYROID GLAND OF FEMALE WISTAR RATS

M. P.Chikhale

Department of Zoology, Rajarshree Shahu Science College, Chandur Rly, Dist.Amravati, Maharashtra, India. 444904.

Corresponding Author - M. P.Chikhale

Email- Maheshchikhale2015@gmail.com

DOI- 10.5281/zenodo.7053063

Abstract

The effects of steroidal and nonsteroidal oral contraceptives on histological changes in the thyroid were studied in female Wistar albino rats for 30 days. The steroidal combined oral contraceptive pill (norgestrel + ethinylestradiol) was diluted to 0.14mg/ ml (Low Dose) , 0.21 mg/ml (dose as per literature) , and 0.43 mg/ ml (high dose). After 30 days of administration of steroidal oral contraceptives at a dose of 0.21 mg/ml/rat/day, follicular colloid levels decreased and follicular cell hypertrophy occurred. In the present study, rats given 0.29 mg/ml/rat/day and 0.43 mg/ml/rat/day non-steroidal tablets exhibited hyperactivity and were filled with colloidal material, but were moderately active. Further research is needed to calculate the perfect dose that does not cause side effects.

Keywords: Steroidal pill, nonsteroidal pills, ontraceptive pill, Thyroid gland, histological alteration, female wistar albino.

Introduction

The term "oral contraception" refers to birth control treatments that are taken orally in order to prevent or delay pregnancy. Both hormonal and non-hormonal oral contraceptive methods give women and couples a variety of options for postponing, spacing out, and limiting pregnancies. Oral contraceptives are well known to affect the serum concentrations of endocrine parameters, which under normal conditions are not involved in the regulation of ovarian activity. It is generally recognised that oral contraceptives can change the levels of endocrine hormones in the serum, which are often unrelated to the regulation of ovarian activity (Wiegratz, et al. 2003). The growth and development of the skeletal system, teeth, epidermis, and central nervous system depend on thyroid hormones in many different ways. The exact proper amount of thyroid hormones must be continuously secreted in order to maintain a regular metabolic rate in the body. A unique feedback mechanism that

uses the hypothalamus and anterior pituitary gland to modulate thyroid function should always be attained (Ganong, 1985). Thyroid hormones, which are also directly correlated with the processes of development and growth, tightly control the metabolism of body proteins. Thyroid hormones and thyroxine-binding globulin are increased during hormonal treatment with oral contraceptives without changes in the thyroidal economy (Pansini, et al. 1987). The main objective of this study is to investigate the effect of steroidal and non-steroidal contraceptive oral pill on thyroid gland histological alteration in the female wistar rats.

Materials And Methods

Experimental Animal Models :-

The present study was carried out in wistar female albino rats weighing about $125g \pm 2 g$. The animals were procured from National Institute of Nutrition (NIN), Hyderabad. Animal experiments were conducted according to "INSA – Ethical guidelines for use of

animals for scientific research after getting permission from ethical committee". The animals were kept in vivarium throughout the period of experiment. They were regularly fed on standard pellet diet provided by National Institute of Nutrition, Hyderabad and water *ad-libitum*. The remaining food and waste matter was removed from the cages on the next day and proper care was taken to avoid any infection. Only healthy rats were used for the present experiments.

Pills:

The experimental female albino rats were given selected steroidal and non-steroidal contraceptive oral pills in calculated doses. Steroidal Contraceptive pill are combined oral contraceptive pill with Brand name was Choice. Each Tablet contains Norgestrel 30 mg and Ethinylestradiol 0.03 mg (Manufactured by : Hindustan latex limited). Non-steroidal oral contraceptive pill with Brand name, Saheli. Each Tablet Contain Centchroman - 30 mg (Manufactured by :- Hindustan Latex Limited).

Doses:

Dilutions of pills were made by using double distilled water (DDW). The combined oral contraceptive pill (norgestrel + ethinylestradiol) was diluted to 0.14mg/ ml (Low Dose) , 0.21 mg/ml (dose as per literature) , and 0.43 mg/ ml (high dose). The non-steroidal oral contraceptive pill (Centchroman) was diluted to 0.29 mg/ ml (Low Dose) , 0.43 mg/ml (dose as per literature) and 0.87 mg/ml (high dose) . The doses of both drugs were calculated as per body weight of rats considering the human consumption and available literature .

Experimental Set Up:-

Experiments were carried out by dividing female albino rats into three groups:

Group I :- Control female albino rats administered orally with 1ml DDW/ rat / day upto 30 days DDW being used as vehicle .

Group II :- Group of combined oral contraceptive pill. This group was again divided into three sub-groups .

Sub-group I :- Experimental female albino rats administered orally with 1 ml norgestrel + ethinylestradiol/ rat / day

upto 30 days. 1 ml dose contains 0.14 mg norgestrel + ethinylestradiol.

Subgroup II:- Experimental female albino rats who received 1ml norgestrel + ethinylestradiol / rat / day upto 30 days . 1 ml dose contains 0.21 mg norgestrel + ethinylestradiol.

Subgroup III :- Experimental female albino rats administered orally with 1 ml norgestrel +ethinylestradiol/rat/day upto 30 days. 1 ml dose contains 0.43 mg norgestrel+ ethinylestradiol.

Group III :- Group of rats were administered orally with Centchroman. This group was divided into three sub groups.

Subgroup I:-Experimental female albino rats administered orally with 1ml Centchroman / rat / day upto 30 days . 1 ml dose contains 0.29 mg Centchroman.

Subgroup II:- Experimental female albino rats administered orally with 1ml Centchroman / rat / day upto 30 days. 1 ml dose contains 0.43 mg Centchroman.

Subgroup III:-Experimental female albino rats administered orally with 1 ml Centchroman / rat / day upto 30 days. 1 ml dose contains 0.87 mg Centchroman .

Histological Studies:

The histological studies were carried out for thyroid gland of the control and experimental female albino rats. The tissues were washed with saline water to remove adhering particles and blood stains and then fixed in Bouin's fixative for 24 hrs. . Then the tissues were washed thoroughly with water, dehydrated with graded series of alcohols and embedded in paraffin wax and sections were cut at 4 to 5 microns. The sections were processed and stained with Haematoxylin - Eosin by standard methods as described by Weissman (1978).

Observation And Result :

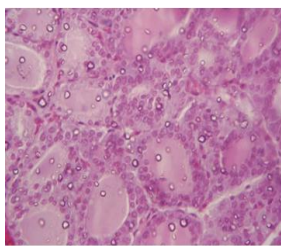
The female albino rats were fed with specific doses of steroidal and non-steroidal contraceptive pills for 30 days. During this experimental period no mortality was observed in all female albino rats administered orally with vehicle, steroidal combined oral pill (ethinylestradiol + norgestrel) and non-

steroidal oral pill (Centchroman) separately.

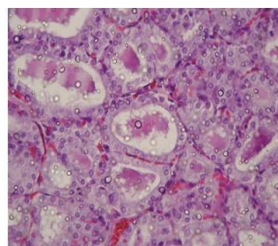
The structure of the control thyroid gland of the albino rat showed normal structure. The follicles exhibited a columnar layer of epithelial cells having their lumen filled with colloidal material. The nuclei of epithelial cells of thyroid follicles are distinct and spherical. The inter follicular connective tissue is thin and even.

After 30 days of treatment with steroidal contraceptive pills with a dose of 0.21 mg/ml/rat/ day, these was decreased colloid in the follicles and hypertrophy of follicular cells (Fig. 136). Almost all the

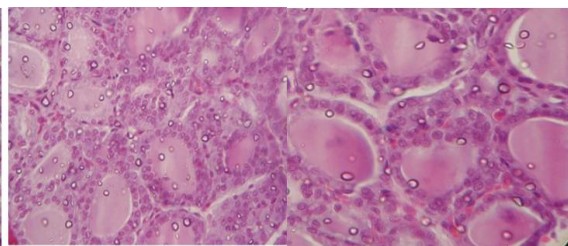
follicles were seen to be degenerating, with flat columnar cells having shrunk nuclei and the connective tissue found loosely arranged in between the follicles in rats which fed with 0.43 mg/ml/rat/ day dose of steroidal contraceptive pills. In rats fed with 0.29 mg/ml/rat/ day and 0.43 mg/ml/rat/ day of non -steroidal pills, exhibited hyper activity, however rats fed with a dose of 0.87 mg/ml/rat/ day of non-steroidal compound showed hyper activity of follicular cells with enlarged nuclei, however, all the follicles were filled with the colloid material.



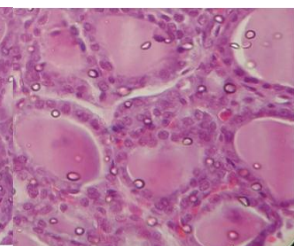
T. S. of thyroid gland of control female albino rat
Haematoxylin-eosin, X400



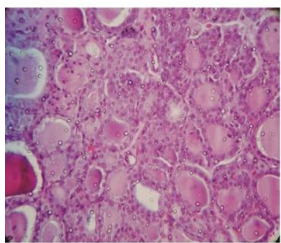
T. S. of thyroid gland of female albino rat fed with
0.21mg/day steroidal contraceptive pill for 30 days.
Haematoxylin-eosin, X400



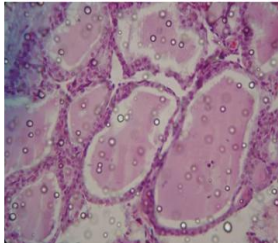
T. S. of thyroid gland of control female albino rat
Haematoxylin-eosin, X400



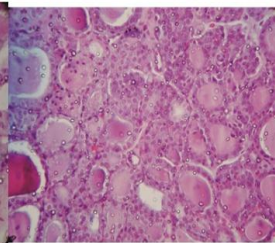
T. S. of thyroid gland of female albino rat fed with
0.87mg/day non-steroidal contraceptive pill for 30 days.
Haematoxylin-eosin, X400



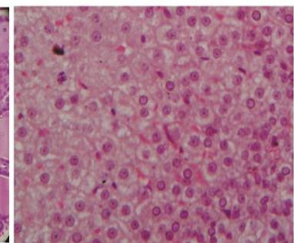
T. S. of thyroid gland of female albino rat fed with
0.14mg/day steroidal contraceptive pill for 30 days.
Haematoxylin-eosin, X400



T. S. of thyroid gland of female albino rat fed with
0.43 mg/day steroidal contraceptive pill for 30 days.
Haematoxylin-eosin, X400



T. S. of thyroid gland of female albino rat fed with
0.14mg/day steroidal contraceptive pill for 30 days.
Haematoxylin-eosin, X400



T. S. of adrenal cortex of control female albino rat ..
Haematoxylin-eosin, X400

Discussion and Conclusion

The female albino rats of approximately same age and weight were fed with three different doses of steroidal pills containing ethinyl estradiol and norgestrel for 30 days and also three different doses of non-steroidal Centchroman contraceptive pills. It is known that long-term use of oral contraceptives (OCs) can cause various side effects on endocrine functions (Brain et.al., 1964) and induced hypertrophy and hyperplasia in the morphology of the thyroid gland. These effects were dose related. After 30 days of treatment with steroidal contraceptive pills with a dose of 0.21 mg/ml/rat/ day, these was decreased colloid in the follicles and hypertrophy of follicular cells. In present study, rats fed with 0.29 mg/ml/rat/ day and 0.43

M. P.Chikhale

mg/ml/rat/ day of non -steroidal pills, exhibited hyper activity were filled with the colloid material but in a normal state of follicles during moderate activity, the cells are simple cuboidal, and the cavity is filled with a reasonable amount of colloid (Shoyele O, et.al, 2019). The collide is composed of thyroglobulin, an iodinated glycoprotein, which is an inactive storage form of thyroid hormone (Lee J et.al, 2016). The thyroid gland is responsible for secreting thyroid hormones (THs), including triiodothyronine (T3) and thyroxine (T4), both of which are mainly generated by thyroid follicular epithelial cells (Kelly, 2000). After entering into the blood, THs are rapidly transported to target tissues, where they facilitate the body's utilization of energy and support the functions of vital organs, including

maintaining the normal function of the reproductive system (Ren and Yan Zhu , 2022). It has since been largely confirmed that significant associations do exist between thyroid disorders and abnormalities of the reproductive system hypothyroidism in females have been well documented to produce variable degrees of gonadal dysfunction (Krassas GE, 2000). In this study both steroidal and non-steroidal contraceptives have obvious effects on thyroid function. More research is needed to calculate the perfect dose which to avoid permanent effects of these drugs.

References :

1. Brain L, Parkers AS, Bishop FMP. Some medical aspects of oral contraceptives. *Lancet* 1964; 2:1329-32.
2. Ganong, W. F. (1985) .The thyroid gland, *Medical physiology*. 12th ed. Lange. (18):258.
3. Kelly, G.S. (2000), Peripheral metabolism of thyroid hormones: A review. *Altern. Med. Rev.*, 5, 306–333
4. Krassas GE 2000 Thyroid disease and female reproduction (modern trends). *Fertil Steril* 74:1063–1070
5. Lee J, Yi S, Kang YE, Kim HW, Joung KH, Sul HJ, Kim KS, Shong M. Morphological and Functional Changes in the Thyroid Follicles of the Aged Murine and Humans. *J Pathol Transl Med*. 2016 Nov;50(6):426-435.
6. Ren and Yan Zhu (2022) , A New Perspective on Thyroid Hormones: Crosstalk with Reproductive Hormones in Females Bingta, *Int. J. Mol. Sci.*, 23, 2708.
7. Shoyele O, Bacus B, Haddad L, Li Y, Shidham V. Lymphoproliferative process with reactive follicular cells in thyroid fine-needle aspiration: A few simple but important diagnostic pearls. *Cytojournal*. 2019;16:20.
8. Wiegratz, I. kutschera, E. lee, J. H. Moore, C. Mellinger, U. Winkler, U.H. and Kuhl, H. (2003). Effect of four oral contraceptives on thyroid hormones, adrenal and blood pressure parameters, Department ofobstetrics and Gynecdogy Geothe University(67): 361- 366.